

Endoscopic Finding of Large Gastric Diverticulum with Ulceration: A Rare Cause of Upper Gastrointestinal Bleeding

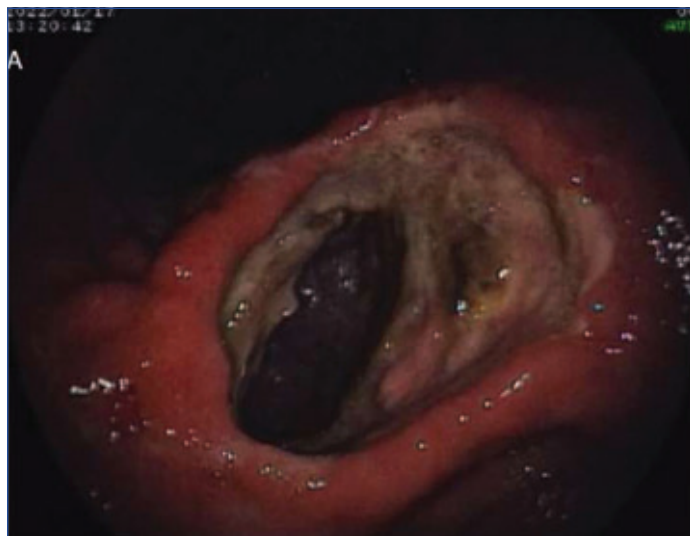KAMLESH ASHOK TAORI¹, VIJENDRA VASANTRAO KIRNAKE²,
PARMESHWAR JUNARE³, SOURYA ACHARYA⁴, NIKHIL PANTBALEKUNDRI⁵



Keywords: Anaemia, Abdomen, Diverticulectomy

A 60-year-old male patient presented to the casualty with complaints of multiple episodes of bloody vomiting, burning epigastric pain, generalised weakness, giddiness, and passing black tarry stools for five days. The epigastric pain had an insidious onset, a burning character, was intermittent, non-radiating, aggravated after consuming spicy food, and relieved by taking some antacid medication. He also had nausea followed by multiple episodes of vomiting, containing fresh red blood, around 1-2 teaspoons in each vomit, with some reddish-black clots. He also had a past history of a burning sensation in the epigastrium for one year. He had no significant family history.

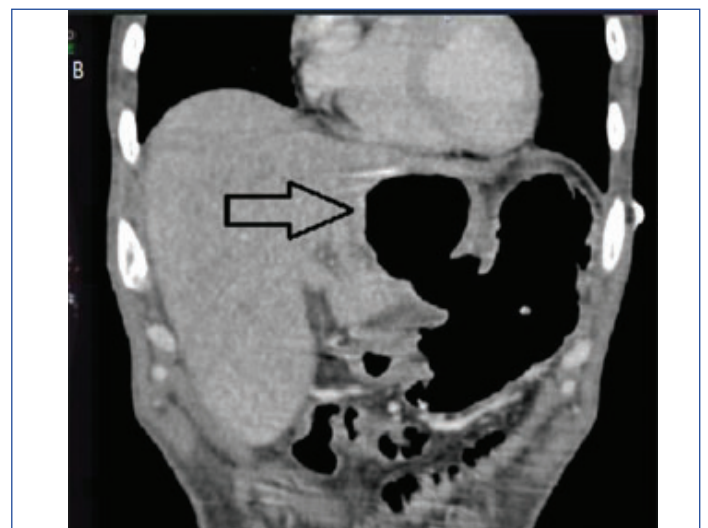Upon examination, he was found to be hypotensive (blood pressure: 90/60 mmHg), tachycardiac (heart rate: 102/min), and tachypnoeic (respiration rate: 24/min); he also had pallor. Laboratory tests revealed normocytic normochromic anaemia (haemoglobin: 8.2 gm%). Stool for occult blood was positive. During endoscopy, a large opening was observed arising from the posterior wall of the stomach body, showing an ulcerated surface with visible blood vessels, suggestive of Gastric Diverticulum (GD) with ulceration [Table/Fig-1].



[Table/Fig-1]: Endoscopic image of a large Gastric Diverticulum (GD) with ulceration.

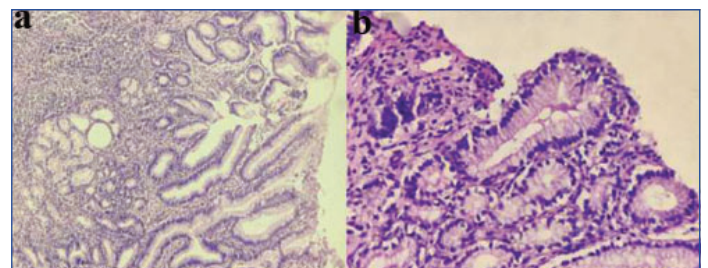
Contrast Enhanced Computed Tomography (CECT) of the abdomen revealed a well-demarcated saccular outpouching at the lesser curvature of the stomach body, suggestive of GD (approximately 6.6×4.8 cm) [Table/Fig-2].

An endoscopy-guided biopsy was taken from the diseased area. The biopsy specimens were stained with Haematoxylin and Eosin stain (A-low power view: 10x [Table/fig: 3(a)] and B-high-power view: 40x [Table/fig: 3(b)]) and showed mucosal atrophy with mild dysplastic changes. The underlying submucosal tissue showed an abundant chronic inflammatory infiltrate composed predominantly



[Table/Fig-2]: Contrast Enhanced Computed Tomography(CECT) abdomen showing a Gastric Diverticulum (GD) (approximately, 6.6×4.8 cm) along lesser curvature of body of stomach.

of lymphocytes and plasma cells. Occasional neutrophils and eosinophils were also seen, along with congested blood vessels. The histopathological features were suggestive of "Chronic Gastritis." The diagnosis of normocytic normochromic anaemia with a large GD and chronic gastritis was made.



[Table/Fig-3]: Haematoxylin and Eosin staining of biopsy specimen suggesting features of Chronic Gastritis: a) low power view (10x), and b) high-power view (40x).

He was advised to undergo diverticulectomy and, if required, subtotal gastrectomy. However, he was unwilling to undergo surgery. As a result, he was managed conservatively with proton-pump inhibitor infusion (Pantoprazole-80 mg i.v. bolus followed by 8 mg/hour for another 72 hours), sucralfate (2 teaspoons thrice daily for eight days), and blood transfusion (2 units of packed red cells) during his two-week stay in the hospital. He was discharged after stabilisation on proton pump inhibitors (Esomeprazole 40 mg daily for 3 months) and a haematinic (Ferrous Sulfate 325 mg tablet for 3 months), with a haemoglobin level of 10.9 gm% at the time of discharge. After three months, the patient was followed clinically and was found

to be symptomatically better, i.e., he had no epigastric burning pain, bloody vomiting, giddiness, or black stools thereafter.

DISCUSSION

A Gastrointestinal Diverticulum (GD) is a small sac or pouch that protrudes outward from the walls of the digestive tract, most commonly in the colon [1]. Diverticulum in the stomach is extremely rare, with a prevalence of 0.04% on radiological examination [2] and 0.01-0.11% on endoscopic examination [3]. GD is more common in old age, specifically in the fifth and sixth decades, with no gender predominance [4]. The common location for GD is the posterior wall of the gastric wall near the gastro-oesophageal junction [4].

GD can occur congenitally or be acquired later in life. These diverticula can develop due to various factors [5], including:

- **Weakness in the stomach wall:** Gastric diverticula often develop when there is a weakness or defect in the muscular layer of the stomach wall.
- **Increased pressure inside the stomach:** When there is increased pressure within the stomach, it can cause the inner layer of the stomach wall to push through the weaker areas, leading to the formation of diverticula. For example, impaired gastric motility.
- **Age-related changes:** As the age increases, abrasion occurs in the gastric mucosa physiologically. These may result in GD.
- **Chronic inflammation:** Conditions that cause chronic inflammation of the stomach, such as gastritis or peptic ulcers, can contribute to the development of gastric diverticula.
- **Genetic factors:** Some individuals may have a genetic predisposition to develop GD, such as Ehlers-Danlos syndrome.
- **Diet and lifestyle factors:** Poor diet, such as a low-fibre or high-fat diet, and unhealthy lifestyle choices like smoking and excessive alcohol consumption, can contribute to the development of gastric diverticula.

It is important to note that while these factors are associated with gastric diverticula, the exact cause or combination of causes can vary from person to person.

The differential diagnosis for gastric diverticula that were considered included:

- **Gastric ulcers:** Peptic ulcers can sometimes appear as outpouchings or irregularities on imaging studies, leading to confusion with diverticula.
- **Gastric tumours:** Certain types of gastric tumours, such as gastrointestinal stromal tumours or gastric adenocarcinomas,

can cause bulges or protrusions in the stomach wall that may resemble diverticula.

- **Gastric polyps:** Large polyps may appear as protrusions on imaging and could be mistaken for diverticula.
- **Pseudodiverticula:** They can occur due to conditions such as gastric tuberculosis or gastric lymphoma.
- **Zenker's diverticulum:** Although not located in the stomach, Zenker's diverticulum is a condition in which a pouch develops in the upper oesophagus. It can sometimes cause symptoms similar to gastric diverticula.

GD is mostly asymptomatic; however, it can occasionally present with symptoms of dyspepsia, abdominal pain, vomiting, perforation, or bleeding [4]. Most GDs have a size ranging from 1-3 cm in diameter. Major complications of GD, such as bleeding leading to shock, perforation, or torsion, are more likely to occur when the GD diameter is more than 4 cm [4]. Individuals with a long-standing history of vague gastrointestinal complaints should undergo prompt investigation, such as endoscopy and/or radiology. GD can be diagnosed through endoscopy or radiology. To determine an accurate diagnosis, a comprehensive evaluation including clinical history, physical examination, imaging studies (such as barium swallow, endoscopy, or CT scan), and possibly biopsy or additional tests may be necessary. For asymptomatic GD, no treatment is indicated [6]. However, persistent medically refractory symptoms or complications prompt surgical resection, specifically diverticulectomy, which is recommended. Laparoscopic resection can be considered for faster recovery and a shorter hospital stay [6].

REFERENCES

- [1] Shah J, Patel K, Sunkara T, Papafragkakis C, Shahidullah A. Gastric diverticulum: A comprehensive review. *Inflamm Intest Dis*. 2019;3(4):161-66. Doi: 10.1159/000495463.
- [2] Di Muzio B, Anan R, Niknejad M, et al. Gastric diverticulum. Reference article, *Radiopaedia*.org (Accessed on 14 Jul 2023) <https://doi.org/10.53347/rID-29784>.
- [3] Al Ghadeer HA, Al Hassan AS, AlAli NH, Almusharaf AJ, Al Dawood MM, Alghazal MM, et al. An incidental finding of asymptomatic gastric diverticula. *Cureus*. 2022;14(11):e31250. Doi: 10.7759/cureus.31250.
- [4] Akkari I, Mraiedha MH, Jemni I, Mrabet S, Hamila F, Jazia IB, et al. Gastric diverticula as a diagnostic and therapeutic challenge: Case report and review of literature. *Int J Surg Case Rep*. 2020;70:93-95. Doi: 10.1016/j.ijscr.2020.04.053. Epub 2020 May 11. PMID: 32417742; PMCID: PMC7229412.
- [5] Rezapour M, Ali S, Stollman N. Diverticular disease: An update on pathogenesis and management. *Gut Liver*. 2018;12(2):125-32. Doi: 10.5009/gnl16552. PMID: 28494576; PMCID: PMC5832336.
- [6] Singh P, Raynor K, Froes C. Gastric antral diverticula: A rare diverticula with a unique presentation. *Case Rep Gastrointest Med*. 2021;2021:6623183. Doi: 10.1155/2021/6623183. PMID: 33854803; PMCID: PMC8019394.

PARTICULARS OF CONTRIBUTORS:

1. Senior Resident, Department of Gastroenterology, JNMC DMIHER, Wardha, Maharashtra, India.
2. Professor and Head, Department of Gastroenterology, JNMC DMIHER, Wardha, Maharashtra, India.
3. Assistant Professor, Department of Gastroenterology, JNMC DMIHER, Wardha, Maharashtra, India.
4. Professor and Head, Department of General Medicine, JNMC DMIHER, Wardha, Maharashtra, India.
5. Resident, Department of General Medicine, JNMC DMIHER, Wardha, Maharashtra, India.

NAME, ADDRESS, E-MAIL ID OF THE CORRESPONDING AUTHOR:

Nikhil Pantbalekundri,
Resident, Department of General Medicine, Jawaharlal Nehru Medical College,
Datta Meghe Institute of Higher Education & Research, Sawangi Meghe,
Wardha-442004, Maharashtra, India.
E-mail: nikhil2623pant@gmail.com

AUTHOR DECLARATION:

- Financial or Other Competing Interests: None
- Was informed consent obtained from the subjects involved in the study? Yes
- For any images presented appropriate consent has been obtained from the subjects. Yes

PLAGIARISM CHECKING METHODS: [Jain H et al.]

- Plagiarism X-checker: Apr 21, 2023
- Manual Googling: Jul 14, 2023
- iThenticate Software: Jul 24, 2023 (6%)

ETYMOLOGY: Author Origin

EMENDATIONS: 5

Date of Submission: **Apr 18, 2023**
Date of Peer Review: **Jul 12, 2023**
Date of Acceptance: **Jul 26, 2023**
Date of Publishing: **May 01, 2023**